

Mesenchymal stem cell application in dental implantology related bone augmentation procedures: A review of the literature

Ozgur Erdogan^{1*} and Nuttawut Supachawaroj²

Faculty of Dental Medicine, Rangsit University, Pathumthani 12000, Thailand,
¹Email: ozgerdogan@yahoo.com, ²Email: nutty_supa@hotmail.com

*Corresponding Author

Submitted 19 November 2014; accepted in final form 9 April 2015
Available online 26 December 2015

Abstract

Bone augmentation procedures are unavoidable surgical procedures for the clinicians, who perform dental implant therapy for the rehabilitation of edentulous ridges. Many types of bone substitutes or graft materials are used for this purpose. Despite its several disadvantages, autogenous bone grafts still remain the gold standard graft materials. Contemporary literature suggests that utilization of mesenchymal stem cells in alveolar bone augmentation procedures can be a feasible alternative to autogenous bone grafts. In this review paper clinical outcomes of intraoperative use of adult mesenchymal stem cells in various Bone Augmentation procedures have been evaluated.

Keywords: mesenchymal stem cells, bone augmentation procedures, dental implant therapy, osteogenesis

บทคัดย่อ

กระบวนการปลูกกระดูกเป็นวิธีการรักษาที่ให้ผลได้ไม่แน่นอนในการรักษาของผู้ทำกรักษาทางทันตกรรมรากเทียมเพื่อฟื้นฟูสภาพสันเหงือกที่ปราศจากฟัน. มีกระดูกและวัสดุที่ใช้ปลูกถ่ายหลายชนิดที่ถูกใช้เพื่อวัตถุประสงค์นี้. การปลูกถ่ายกระดูกอัดมันยังคงเป็นมาตรฐานที่ดีที่สุด. ในวัสดุปลูกถ่ายถึงแม้จะยังคงมีข้อเสียเปรียบหลายประการ. วรรณกรรมปัจจุบันได้มีการแนะนำการใช้ มีเซนไคมอล สเต็ม เซลล์ เป็นหนึ่งในทางเลือกที่ดีในการปลูกกระดูกเข้าฟัน. บทความนี้ได้ทบทวนถึงผลการประเมินของการใช้ เซลล์ต้นกำเนิดมีเซนไคม์ในกระบวนการการฟื้นฟูสภาพต่างในช่องปากทางคลินิก

คำสำคัญ: เซลล์ต้นกำเนิดมีเซนไคม์, การฟื้นฟูสภาพช่องปาก, การรักษาทางทันตกรรมรากเทียม, การสร้างกระดูก

1. Introduction

The success and predictability of dental implant therapy are well established. The survival rates for various types root form implants has been reported between 90-98% for 5 years and 89-95% for 10 years (Klokkevoeld & Han, 2007). Therefore, dental implant therapy has become a routine recommended treatment option for the rehabilitation of edentulous alveolar ridges. Dental implant surgery requires additional bone augmentation procedures in many cases (Erdogan, Shafer, Taxel, & Freilich, 2007; Kaigler et al., 2013; Khojasteh, Behnia, Dashti, & Stevens, 2012).

The term "alveolar bone augmentation" refers to any attempt to preserve or increase the height or the width of the residual ridge, or the repair of defects with grafts or biomaterials. These techniques include ridge preservation after tooth extraction, onlay autogenous bone block grafting, guided bone regeneration techniques, inlay or

interpositional grafting, distraction osteogenesis, and ridge expansion/splitting techniques. After augmentation surgery, bone healing and the incorporation of the graft include a cascade of events involving osteogenesis, osteoclastic resorption, osteoinduction, and osteoconduction. Osteogenesis is a general term that refers to the ability of bone to regenerate itself by producing new bone; a function accomplished by osteoblasts. Osteoclastic resorption removes bone mineral from the bone matrix, and is mediated by osteoclasts. Osteoinduction is the stimulation of new bone formation through the recruitment of osteoprogenitor mesenchymal cells from the surrounding host bed. The bone graft serving as a scaffold for the in-growth of vessels, perivascular tissue, and mesenchymal cells from the host bed exhibits the characteristic of osteoconduction. This scaffold allows gradual replacement of bone graft over time by resorption of old bone trabeculae and formation of new bone. (Erdogan et al., 2007).

Remodeling of bone is regulated by a combination of resorption and bone formation. The primary cells involved are osteoblasts that form bone and osteoclasts that resorb bone (Roberts & Hartsfield, 2004). There is a close anatomic and functional relationship between resorptive and formative cells at remodeling sites. These cells show their action within a temporary anatomic structure called the basic multicellular unit (BMU) (Sikavitsas, Temenoff, & Mikos, 2001). A mature BMU consists of a leading front of osteoclasts followed by osteoblasts, blood supply, and the associated connective tissue. In the remodeling process, the entire BMU moves forward, and osteoclasts resorb bone and die via apoptosis. Successful incorporation of a bone graft material without vascularity or osteogenic capacity such as calcium phosphate based graft materials depends on the bone remodeling capacity of the recipient bone.

The type of the augmentation procedure depends on the size of the bone defect, particular clinical condition, patients or surgeons' preferences or cost of the applied method. Bone augmentation procedures can be performed as a separate surgery prior implant placement surgery, thus called 2-stage augmentation. In cases, where limited alveolar ridge resorption exists, the procedure can be applied concomitant with implant placement. Eliminating an additional surgery has several advantages such as reduced treatment time, reduced cost, and increased patient acceptance. Bone augmentations concomitant with implant placement are therefore most applied bone augmentation procedures in dental implant surgery (Ito, Yamada, Naiki, & Ueda, 2006). The principle application of by this means is through the so called "guided bone regeneration" (GBR) technique. GBR technique in one stage dental implant surgery involves application of autogenous or exogenous bone graft materials around dental implant to regenerate new bone. The bone graft is covered by a resorbable or non-resorbable membrane in order to create a space thus providing guidance for regenerating bone (Erdogan et al., 2007).

There are numerous studies available, which tried to find out the best bone graft material for the augmentation of bone defects around dental implants. Currently, autogenous bone grafts are considered the gold standard as bone augmentation material, since they contain living cells thus promoting osteogenic activity. Commonly used bone grafts such as Beta-Tricalcium phosphate, hydroxyapatite and xenogenic bone grafts, which

undergo several deproteinization and sterilization phases totally lack of osteogenic capacity. It is claimed that some allogenic bone graft materials contain certain amount of osteogenic protein and have osteo-inductive capacity (Soost et al., 2001). However, there is no strong evidence showing superior features of allogenic bone grafts over xenogenic bone grafts with regard to bone regeneration capacity in oral surgical procedures.

Numerous studies in the literature evaluated the outcomes of the installment osteoinductive or osteogenic capacity to bone grafts by utilizing bone morphogenetic protein (BMP) or mesenchymal stem cells (MSC) in the bony reconstruction procedures.

1.1 Bone morphogenetic proteins

After the recognition of the essential role of growth factors in bone healing mechanism, the use of growth factors in bone regeneration procedures has become a popular issue. Bone morphogenetic proteins (BMPs), which belong to transforming growth factor family, are the most popular growth factors to be used in bone related applications. Twenty subtypes of BMPs have been discovered so far and the number of subtypes discovered is increasing in every upcoming year (Spagnoli & Marx, 2011). The interest has enormously increased after Dr. Marshall Urist's sensational discovery in 1965, which show that BMP can induce ectopic bone formation.(Urist, 1965). We know that out of 20 BMP subtypes discovered so far, BMP-2 and BMP-7 are the two with highest osteogenic potentials. Both BMP subtypes are commercially available in the US to be used in bone regeneration procedures (Spagnoli & Marx, 2011). Clinical studies mostly report very good outcomes of BMPs in sinus floor elevation procedures, alveolar cleft repair and extraction socket preservation procedures. BMP-2 has FDA approval to be used in such oral surgery procedures (Spagnoli & Marx, 2011). Biggest questions about BMPs are unwanted excessive bone formation and neoplastic transformation at the recipient site. The most reported unwanted effect of BMP application is severe postoperative edema (Spagnoli & Marx, 2011). BMPs still remain as one of the candidates for becoming the gold standard material as the research seeking the optimal dosing and delivery method continues.

1.2 Mesenchymal stem cell applications

Stem cells are immature, unspecialized cells

that have the potential to develop into many different cell lineages via differentiation. There are two primary sources of stem cells: adult stem cells and embryonic stem cells (Khojasteh et al., 2012). Many types of adult stem cells reside in several mesenchymal tissues, and these cells are collectively referred to as mesenchymal stem cells (MSCs) or multipotent mesenchymal stromal cells. MSCs have been used successfully in the treatment of various conditions and diseased organs as well as in the treatment of bone defect to augment bone tissue. MSCs can be delivered and applied to recipient site by various methods. One of the most commonly applied methods involves an aspiration made from the patients' own bone marrow. The preferred bone is usually iliac bone for this purpose. Bone marrow aspirate is known to contain high amount of MSCs (Jakobsen, Sørensen, Kassem, & Thygesen, 2013). This aspirate can be applied directly to the recipient site in conjunction with other graft materials or MSCs can be concentrated by special centrifuge methods. The major disadvantage of this technique is that the quantity and quality of MSCs can be assured only by very complicated ways. Another application method of MSCs is colonization of MSCs, which are taken from the patient, in cell cultures *in vitro*. High quality MSCs can be produced in desired amount using this method. For both application methods the presence of the MSCs should be identified on the molecular level based on positivity for several tissue markers such as CD90, CD105, CD44, CD29, CD160, and CD119, and negativity for others such as CD14, CD45, CD34, and CD11 (Khojasteh et al., 2012). As MSCs are multipotential cells, extracted cells can be differentiated into bone, cartilage, and adipose cells *in vitro*. The osteogenic potency of MSCs can be estimated by assessing levels of alkaline phosphatase activity, osteocalcin, osteopontin, calcium deposition, expression of osteogenic genes, and alizarin red staining and cell morphology (de Girolamo et al., 2007).

Although MSCs can be obtained from various tissues such as periodontium, dental pulp or salivary glands, the most commonly used source is bone marrow. Albeit considered a relatively safe and easy procedure bone marrow aspiration is often associated with pain and may cause serious complications such as postoperative infection and bleeding. Adipose tissue is another source of adult stem cells with osteoblastic differentiation capacity (Hjortholm, Jaddini, Hałaburda, & Snarski, 2013).

Adipose tissue is superficially located and can be derived in large amounts with liposuction method under local anesthesia. Patients may prefer liposuction procedure over bone marrow aspiration since adipose tissue is generally an unwanted tissue by most of the population. Because of high patient preferences, tissue engineering applications using cells isolated from adipose tissue is becoming more popular in clinical settings (Sterodimas et al., 2012). Furthermore, our previous experience showed that handling and processing of adipose tissue is easier than the bone marrow, as rapid coagulation of bone marrow causes decreased amount of available living cells.

1.3 Scaffolds

One important aspect of the success of the MSCs application is the scaffold, in which the MSCs are delivered to the recipient site. Scaffolds can be classified as organic or inorganic. The materials that have been used in the previous studies include bovine bone mineral (BBM), commercially available cell-enhanced bone graft, polymer fleece, HA/ β -TCP, platelet-rich plasma (PRP), polyglycolic-poly-lactic acid (PLGA), β -TCP, HA, freeze-dried autogenous bone and collagen sponges (Jakobsen et al., 2013). Different scaffold materials have their specific advantages and disadvantages. The clinician should choose the scaffold material according to the clinical condition that is attempted to be treated by utilizing MSCs.

1.4 Previous *in vivo* and clinical studies

Tissue engineering involving mesenchymal stem cell (MSC) transplantation is one of the most promising treatment ideas for regenerating bone. The number of previously published studies regarding utility of MSCs in the treatment of Peri-implant bone defect is limited, however most of them report excellent results. Most of the studies used cells from bone marrow. Other sources of cells were adipose tissue, periosteum, dental pulp and periodontal ligament.

1.5 *In vivo* studies

To our knowledge the first study evaluating bone formation around periimplant defect by utilizing MSCs is the study by Yamada et al published in 2004 (Yamada, Ueda, Naiki, & Nagasaka, 2004). They created periimplant defects in the mandibles of dogs. The defects were treated with 3 different materials and the group, in which the

combination of MSCs and Platelet rich plasma was used, had the best results in terms of bone formation. The authors isolated MSCs from the bone marrow of the same dog. A following study by the same group showed similar results when MSCs were applied with immediate implant placement (Ito et al., 2006).

A study by Kim et al. used stem cells isolated either from the periodontal ligament or bone marrow in the treatment of periimplant bone defects in the mandibles of beagle dogs (Kim et al., 2009). They reported increased bone regeneration with both groups compared to the control group. There was no difference with regard to stem cell origin. A similar study by Ribeiro et al. (2010) compared the efficacy of MSCs isolated either from periosteum or bone marrow in the treatment of periimplant bone defect in beagle dogs (Ribeiro et al., 2010). Both groups showed good results without significant difference between the groups. Another study by Ribeiro et al. evaluated the success of MSCs isolated and cultured from bone marrow in a same dog periimplant defect model (Ribeiro et al., 2012). The authors concluded that defects treated with MSCs either covered with membrane or uncovered had better bone healing than non-treated defects.

Some other studies evaluated non-processed tissues, which potentially carry MSCs in the treatment of periimplant defects. Betoni et al. applied non-processed bone marrow aspirates to the periimplant bone defects in rabbit tibiae (Betoni et al., 2012). After centrifuging the aspirates at 1200 rpm for 10 minutes, the sediments were collected and directly applied to the defects. The authors compared the bone healing with blood cloth and did not found any difference between 2 groups. In this study, the viability, types and numbers of the cells were not confirmed. Another similar study by Matsubara et al. compared non-processed adipose tissue with autogenous bone in the treatment of periimplant defect in rabbit tibia model (Matsubara et al., 2012). They concluded that adipose tissue interfaces with bone formation around implants (Matsubara et al., 2012).

In an unpublished previous study conducted by our research group, the efficacy of bone marrow derived mesenchymal stem cells has been evaluated in the rabbit calvarial model for the onlay bone augmentation procedures. We delivered the MSCs with hydroxyapatite-collagen linked scaffolds in dome shaped titanium cages. Our findings suggest that MSCs can provide successful bone regeneration

that is comparable to autogenous bone grafts in rabbit calvarium model (Figures 1 and 2).

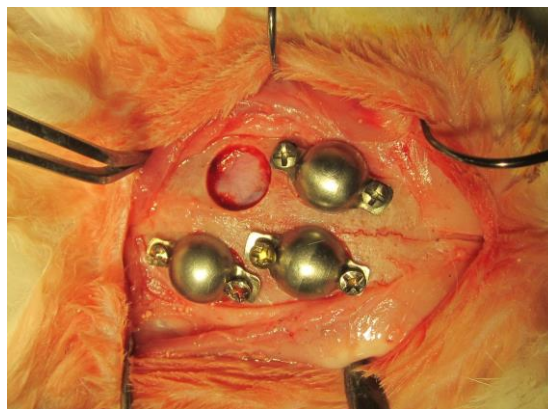


Figure 1 Intraoperative photograph showing placement of mesenchymal stem cell buried titanium domes on the rabbit cranium

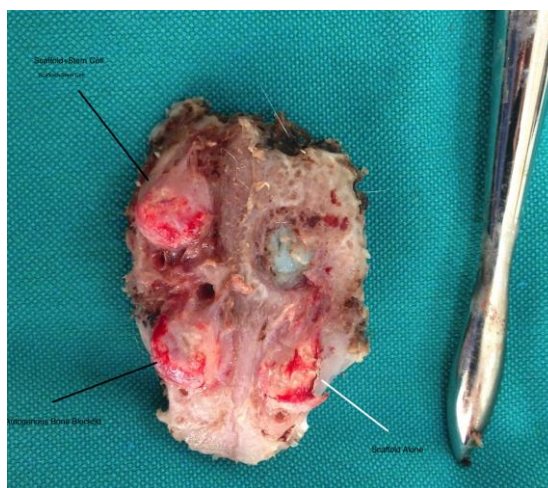

Figure 2 Photograph showing harvested specimen, which indicates successful vertical onlay augmentation with the use of the mesenchymal stem cells.

1.6 Clinical studies

The number of clinical studies, in which MSCs were utilized for the reconstruction of bone defects were increasing for various clinical conditions. A case series by Smiler et al. evaluated the influence of bone marrow aspirate added to xenograft or alloplast graft matrix scaffold to produce bone (Smiler, Soltan, & Lee, 2007). They evaluated the contribution of bone marrow aspirate without further confirmation of the present cells on the maturation of bone grafts applied concomitant with implant placement in 5 patients. The authors concluded that bone marrow aspirate containing

adult stem cells when mixed with bioengineered graft materials provide a scaffold to support the proliferation, differentiation, and maturation of the stem cells, as well as facilitating angiogenesis.

A clinical study by Kaigler et al. compared the success rate of MSCs obtained from patients' bone marrow with conventional guided bone regeneration technique (Kaigler et al., 2013). They demonstrated that MSC therapy accelerated alveolar bone regeneration compared to GBR therapy. In addition, the authors concluded that the treatment significantly reduced the need for secondary bone grafting at the time of oral implant placement with a 5-fold decrease in implant bony dehiscence exposure.

One of the most common indications for MSC application is sinus floor augmentation surgery. More than 15 clinical studies evaluated success of MSCs in sinus floor augmentation so far mostly reporting favorable contribution (Jakobsen et al., 2013). Three of these studies were randomized clinical studies. In one of these randomized clinical studies 12 consecutive patients (age 60.8 ± 5.9 years, range 48–69 years) needing reconstruction of their atrophic maxilla, a bilateral sinus floor augmentation procedure was performed (Rickert et al., 2011). Randomly, on one side the augmentation procedure was performed with bovine bone mineral seeded with mononuclear stem cells harvested from the posterior iliac crest (test group) while BioOss® mixed with autogenous bone (harvested from the retromolar area) was applied on the contra-lateral side (control group). The authors concluded that mesenchymal stem cells seeded on BioOss® particles can induce the formation of a sufficient volume of new bone to enable the reliable placement of implants within a time frame comparable with that of applying either solely autogenous bone or a mixture of autogenous bone and BioOss®. Yamada et al. evaluated the effects of tissue-engineered bone, which was composed of bone marrow-derived mesenchymal stem cells as stem cell source and platelet-rich plasma as an autologous scaffold and signal molecules on osteotome technique with simultaneous implant placement in 23 patients (Yamada, Nakamura, Ueda, & Ito, 2013). The authors showed increased bone volume in subjects treated with MSC therapy. One additional well designed clinical study showed significantly increased bone volume in patients undergoing maxillary sinus floor elevation procedure, in which additional MSC treatment has been added to

conventional bone grafts (Gonshor, McAllister, Wallace, & Prasad, 2011).

Except sinus floor augmentation and guided bone regeneration procedures MSCs have been successfully used in the reconstruction of large bone defects (Mesimäki et al., 2009; Lee et al., 2010) onlay alveolar bone augmentation (Ueda, Yamada, Kagami, & Hibi, 2008), reconstruction of alveolar clefts (Hibi, Yamada, Ueda, & Endo, 2006; Behnia, Khojasteh, Soleimani, Tehranchi, & Atashi, 2012) and the treatment of osteoradionecrosis (Mendonça & Juiz-Lopez, 2010). MSCs have also been applied in with more sophisticated methods e.g. in preformed 3D scaffolds along with tissue engineering procedures (Yamada et al., 2004).

2. Conclusions

It is apparent that dental implant therapy will continue being a reliable treatment option for the rehabilitation of edentulous ridges. Demand for dental implants is increasing tremendously. It is estimated that value of global dental implant market will reach 4.1 Billion US Dollars in 2014 (Maynard, 2013). Alveolar augmentation procedures are inevitable adjuvant procedures and often cause more boredom situations than implant surgery itself. Although, autogenous bone graft is still the gold standard in the treatment of alveolar bone deficiencies, there are some serious alternative treatment methods including MSC applications. Current literature both at in vivo and clinical levels demonstrate promising results and thus indicate that MSC application will be an important role player in implant dentistry. The interest in utilization MSC therapy in implant dentistry is increasing similarly with the other medical applications.

3. References

- Behnia, H., Khojasteh, A., Soleimani, M., Tehranchi, A., & Atashi, A. (2012). Repair of alveolar cleft defect with mesenchymal stem cells and platelet derived growth factors: a preliminary report. *Journal of Cranio-Maxillo-Facial Surgery*, 40(1), 2-7.
- Betoni, W. Jr., Queiroz, T. P., Luvizuto, E. R., Valentini-Neto, R., Garcia-Júnior, I. R., & Bernabé, P. F. (2012). Evaluation of centrifuged bone marrow on bone regeneration around implants in rabbit tibia. *Implant Dentistry*, 21(6), 481-485. DOI: 10.1097/ID.0b013e31826916b6

- de Girolamo, L., Sartori, M. F., Albisetti, W., & Brini, A. T. (2007). Osteogenic differentiation of human adipose-derived stem cells: comparison of two different inductive media. *Journal of Tissue Engineering and Regenerative Medicine*, 1(2), 154-157. DOI: 10.1002/term.12
- Erdogan, O., Shafer, D. M., Taxel, P., & Freilich, M. A. (2007). A review of the association between osteoporosis and alveolar ridge augmentation. *Oral Surgery Oral Medicine Oral Pathology Oral Radiology*, 104, 738.e1-738.e13. DOI: <http://dx.doi.org/10.1016/j.tripleo.2007.04.008>
- Gonshor, A., McAllister, B. S., Wallace, S. S., & Prasad, H. (2011). Histologic and histomorphometric evaluation of an allograft stem cell-based matrix sinus augmentation procedure. *The International Journal of Oral Maxillofacial Implants*, 26(1), 123-131.
- Hibi, H., Yamada, Y., Ueda, M., & Endo, Y. (2006). Alveolar cleft osteoplasty using tissue engineered osteogenic material. *International Journal of Oral and Maxillofacial Surgery*, 35(6), 551-555. DOI: 10.1016/j.ijom.2005.12.007
- Hjortholm, N., Jaddini, E., Hałaburda, K., & Snarski, E. (2013). Strategies of pain reduction during the bone marrow biopsy. *Annals of Hematology*, 92(2), 145-149. DOI: 10.1007/s00277-012-1641-9
- Ito, K., Yamada, Y., Naiki, T., & Ueda, M. (2006). Simultaneous implant placement and bone regeneration around dental implants using tissue-engineered bone with fibrin glue, mesenchymal stem cells and platelet-rich plasma. *Clinical Oral Implants Research*, 17(5), 579-586.
- Jakobsen, C., Sørensen, J. A., Kassem, M., & Thygesen, T. H. (2013). Mesenchymal stem cells in oral reconstructive surgery: a systematic review of the literature. *Journal of Oral Rehabilitation*, 40(9), 693-706. DOI: 10.1111/joor.12079
- Kaigler, D., Pagni, G., Park, C. H., Braun, T., Holman, L. A., Yi, E., . . . Giannobile, W. V. (2013). Stem cell therapy for craniofacial bone regeneration: a randomized, controlled, feasibility trial. *Cell Transplant*, 22(5), 767-777. DOI: 10.3727/096368912X652968
- Khojasteh, A., Behnia, H., Dashti, S.G., & Stevens, M. (2012). Current trends in mesenchymal stem cell application in bone augmentation: a review of the literature. *Journal of Oral and Maxillofacial Surgery*, 70(4), 972-982. DOI: 10.1016/j.joms.2011.02.133
- Kim, S. H., Kim, K. H., Seo, B. M., Koo, K. T., Kim, T. I., Seol, Y. J., . . . Lee, Y. M. (2009). Alveolar bone regeneration by transplantation of periodontal ligament stem cells and bone marrow stem cells in a canine peri-implant defect model: a pilot study. *Journal of Periodontology Online*, 80(11), 1815-1823. DOI: 10.1902/jop.2009.090249
- Klokkevold, P. R., & Han, T. J. (2007). How do smoking, diabetes, and periodontitis affect outcomes of implant treatment? *The International Journal of Oral & Maxillofacial Implants*, 22(Special Supplement), 173-202.
- Lee, J., Sung, H. M., Jang, J. D., Park, Y. W., Min, S. K., & Kim, E. C. (2010). Successful reconstruction of 15-cm segmental defects by bone marrow stem cells and resected autogenous bone graft in central hemangioma. *Journal of Oral and Maxillofacial Surgery*, 68(1), 188-194. DOI: 10.1016/j.joms.2009.08.031
- Matsubara, F. B., Zanicotti, D. G., Zielak, J. C., Giovanini, A. F., Gonzaga, C. C., de Andrade, U. C., & Deliberador, T. M. (2012). Nonprocessed adipose tissue graft in the treatment of dehiscence bone defects in rabbit tibiae: a pilot study. *Implant Dentistry*, 21(3), 236-241. DOI: 10.1097/ID.0b013e3182563e0d
- Maynard, K. (2013). Global Boom in Dental Implants. *British Dental Journal*, 214, 219. DOI: 10.1038/sj.bdj.2013.232
- Mendonça, J. J., & Juiz-Lopez, P. (2010). Regenerative facial reconstruction of terminal stage osteoradionecrosis and other advanced craniofacial diseases with adult cultured stem and progenitor cells. *Plastic and Reconstructive Surgery*, 126(5), 1699-1709.

- Mesimäki, K., Lindroos, B., Törnwall, J., Mauno, J., Lindqvist, C., Kontio, R., . . . Suuronen, R. (2009). Novel maxillary reconstruction with ectopic bone formation by GMP adipose stem cells. *International Journal of Oral and Maxillofacial Surgery*, 38(3), 201-209. DOI: 10.1016/j.ijom.2009.01.001
- Ribeiro, F. V., Suaid, F. F., Ruiz, K. G., Salmon, C. R., Paparotto, T., Nociti, F. H., . . . Casati, M. Z. (2010). Periosteum-derived cells as an alternative to bone marrow cells for bone tissue engineering around dental implants. A histomorphometric study in beagle dogs. *Journal of Periodontology Online*, 81(6), 907-916. DOI 10.1902/jop.2010.090604
- Ribeiro, F. V., Suaid, F. F., Ruiz, K. G., Rodrigues, T. L., Carvalho, M. D., Nociti, F. H., . . . Casati M. Z. (2012). Effect of autologous bone marrow-derived cells associated with guided bone regeneration or not in the treatment of peri-implant defects. *International Journal of Oral and Maxillofacial Surgery*, 41(1), 121-127. DOI: 10.1016/j.ijom.2011.06.025
- Rickert, D., Sauerbier, S., Nagursky, H., Menne, D., Vissink, A., & Raghoobar, G. M. (2011). Maxillary sinus floor elevation with bovine bone mineral combined with either autogenous bone or autogenous stem cells: a prospective randomized clinical trial. *Clinical Oral Implants Research*, 22(3), 251-258. DOI: 10.1111/j.1600-0501.2010.01981.x
- Roberts, W. E., & Hartsfield, J. K. (2004). Bone development and function: genetic and environmental mechanisms. *Seminars in Orthodontics*, 10(2), 100-122. DOI: 10.1053/j.sodo.2004.01.001
- Sikavitsas, V. I., Temenoff, J. S., & Mikos, A. G. (2001). Biomaterials and bone mechanotransduction. *Biomaterials*, 22, 2581-2593.
- Smiler, D., Soltan, M., & Lee, J. W. (2007). A histomorphogenic analysis of bone graftaugmented with adult stem cells. *Implant Dentistry*, 16(1), 42-53. DOI: 10.1097/ID.0b013e3180335934
- Soost, F., Koch, S., Stoll, C., Amthauer, H., Grosse-Siestrup, C., & Zorn, P. (2001). Validation of bone conversion in osteoconductive and osteoinductive bone substitutes. *Cell and Tissue Banking*, 2(2), 77-86.
- Spagnoli, D. B., & Marx, R. E. (2011). Dental implants and the use of rhBMP-2. *Oral and Maxillofacial Surgery Clinics of North America*, 23(2), 347-361.
- Sterodimas, A., Boriani, F., Magarakis, E., Nicaretta, B., Pereira, L.H., & Illouz, Y.G. (2012). Thirty four years of liposuction: past, present and future. *European Review of Medical and Pharmacological Sciences*, 16(3), 393-406.
- Ueda, M., Yamada, Y., Kagami, H., & Hibi, H. (2008). Injectable bone applied for ridge augmentation and dental implant placement: human progress study. *Implant Dentistry*, 17(1), 82-90. DOI: 10.1097/ID.0b013e31815cd591
- Urist, M.R. (1965). Bone: formation by autoinduction. *Science*. 150(3698), 893-899. DOI: 10.1126/science.150.3698.893
- Yamada, Y., Ueda, M., Naiki, T., & Nagasaka, T. (2004) Tissue-engineered injectable bone regeneration for osseointegrated dental implants. *Clinical Oral Implants Research*, 15(5), 589-597. DOI: 10.1111/j.1600-0501.2004.01038.x
- Yamada, Y., Nakamura, S., Ueda, M., & Ito, K. (2013). Osteotome technique with injectable tissueengineered bone and simultaneous implant placement by cell therapy. *Clinical Oral Implants Research*. 24(4), 468-474. DOI: 10.1111/j.1600-0501.2011.02353.x